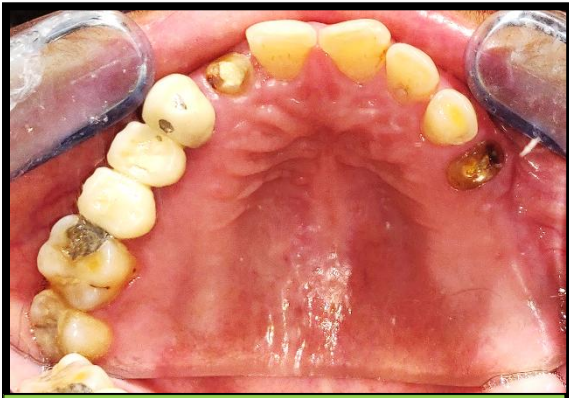

## RESTORATION OF MISSING ANTERIOR TOOTH USING CUSTOM POST AND CORE

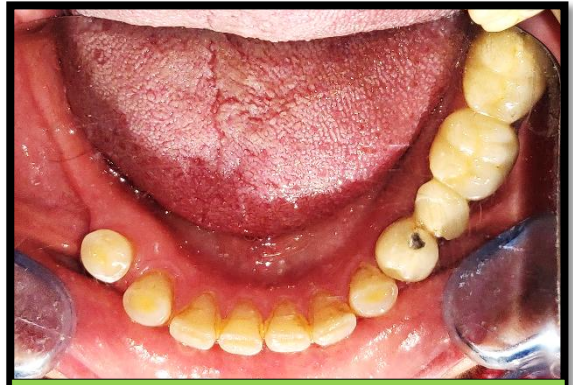|                               |  |
|-------------------------------|--|
| <b>NAME</b>                   | Mrs. Tara  |
|                               | 20180615422  |
| <b>AGE/SEX</b>                | 42/Female  |
| <b>CHIEF COMPLAINTS</b>       | Patient complains of fractured tooth in upper front region since 3 months  |
| <b>INTRA- ORAL FINDINGS</b>   | <ul style="list-style-type: none"><li>❖ High arch palate</li><li>❖ Missing 25 26 27 45 46 47</li><li>❖ Adequate inter-arch space</li><li>❖ Calculus and stains present</li></ul> |
| <b>RADIO GRAPHIC FINDINGS</b> | No relevant radiological findings  |
| <b>DIAGNOSIS</b>              | Ellis class IV wrt 12  |
| <b>TREATMENT EXECUTED</b>     | Restoration of 12 tooth using custom fabricated cast post and core   |



Pre treatment patient profile



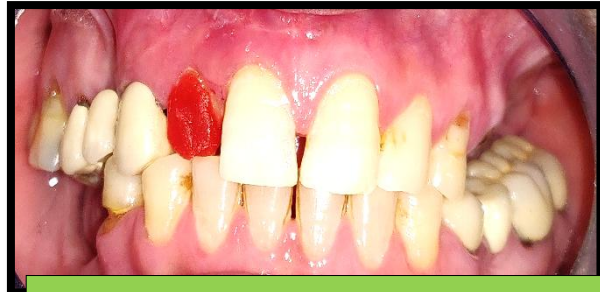Maxillary ridge



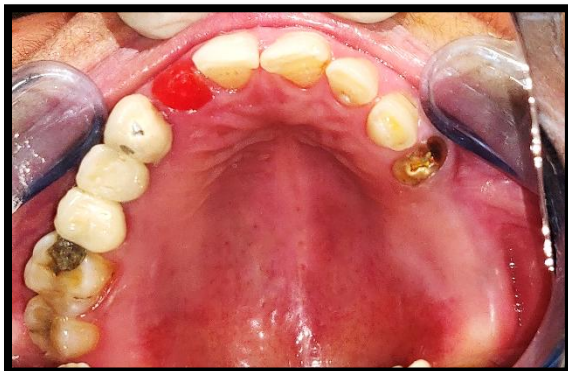Mandibular ridge



Customized post and core of pattern resin



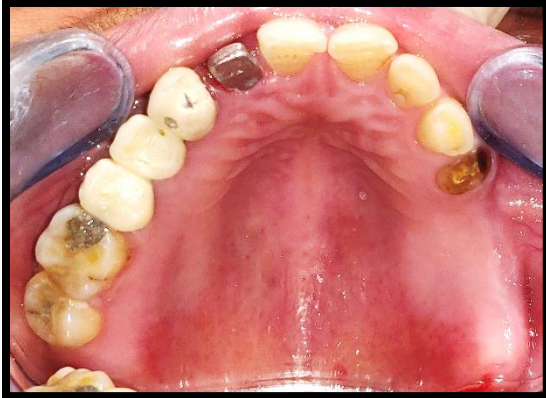Frontal view of customized pattern resin post and core



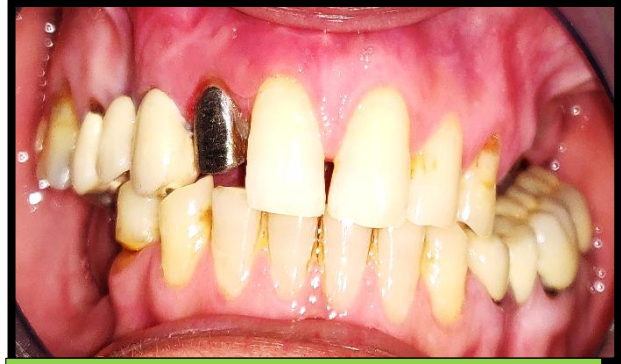Occlusal view of customized pattern resin post and core



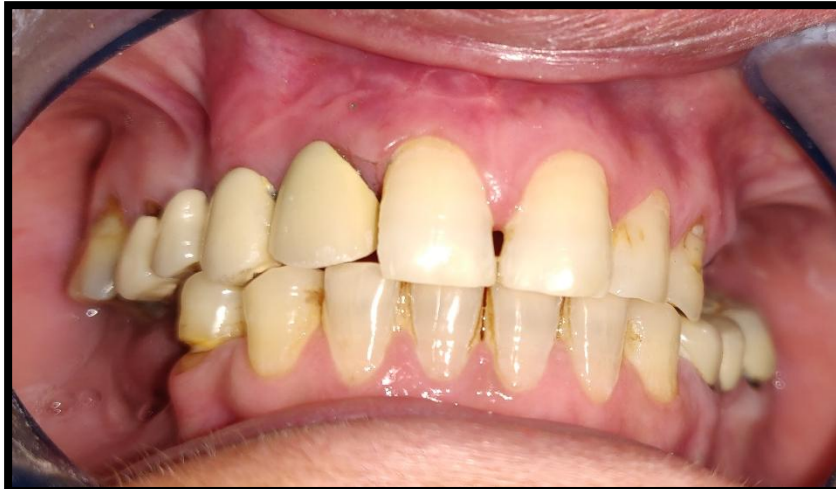Casted post and core




Insertion of casted post and core (occlusal view)



Insertion of casted post and core (frontal view)



Final PFM prosthesis



Post treatment patient frontal profile