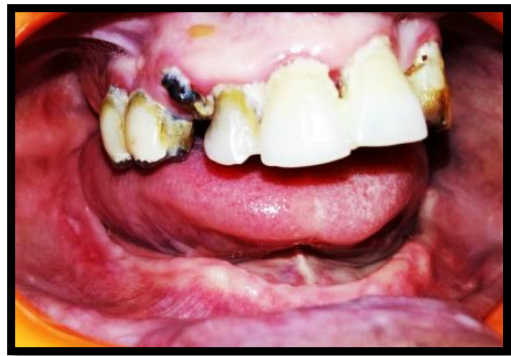
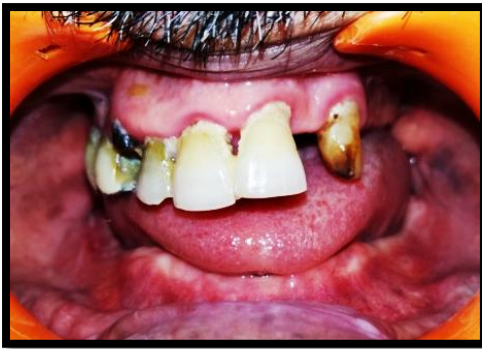

MANDIBULAR IMPLANT SUPPORTED OVERDENTURE USING BALL ATTACHMENTS

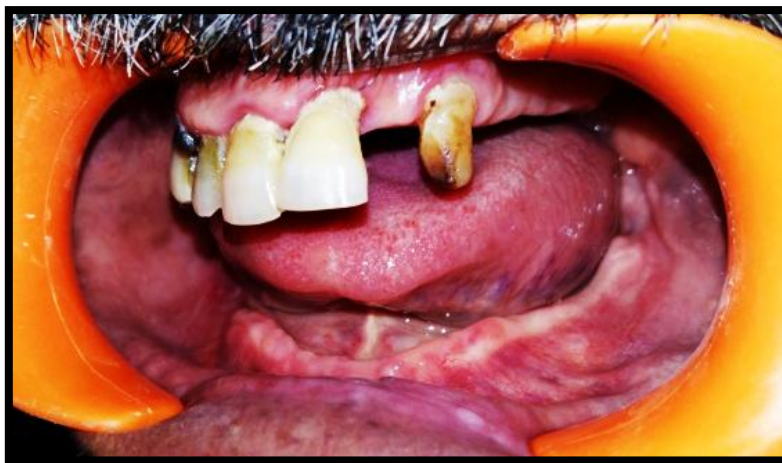NAME	Mr. Shyam
C R NO.	20171215377
AGE/SEX	56/male
CHIEF COMPLAINTS	Unable to chew last 4 year and poor in appearance
INTRA- ORAL FINDINGS	<ul style="list-style-type: none">❖ edentulous mandibular ridge and partially dentate maxillary ridge❖ Adequate inter-arch space❖ Calculus and stains present
RADIO GRAPHIC FINDINGS	No relevant radiological findings
DIAGNOSIS	mandibular ridge
TREATMENT EXECUTED	Fabrication of mandibular implant supported overdenture using ball attachments

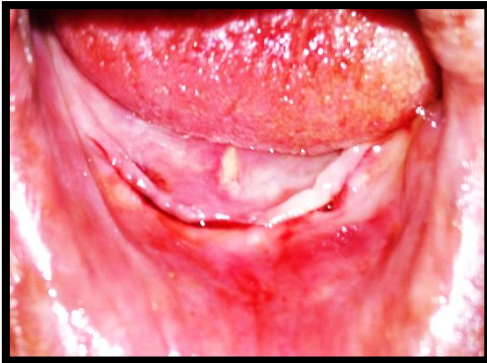

FRONTAL VIEW

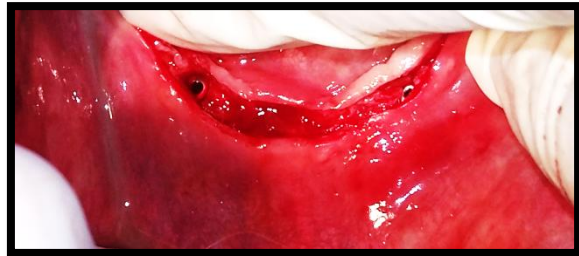


INTRA ORAL PHOTOGRAPHS

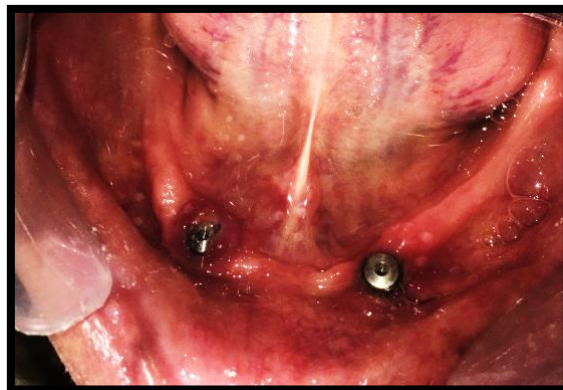



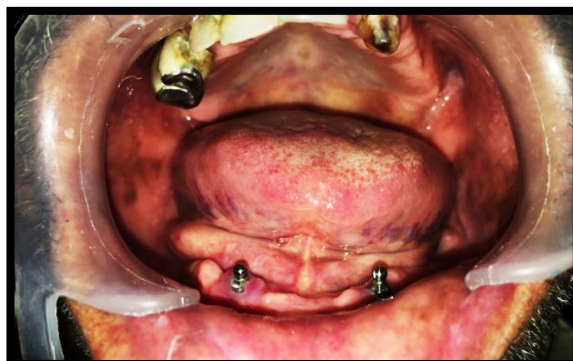
INCISION



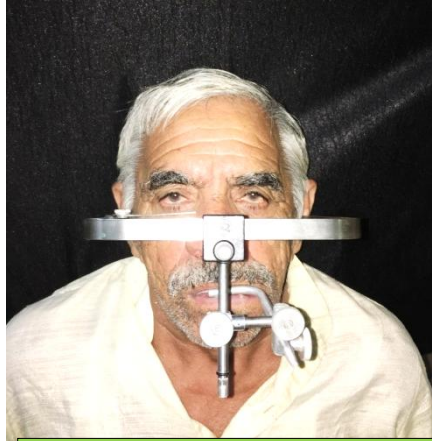IMPLANT PLACED



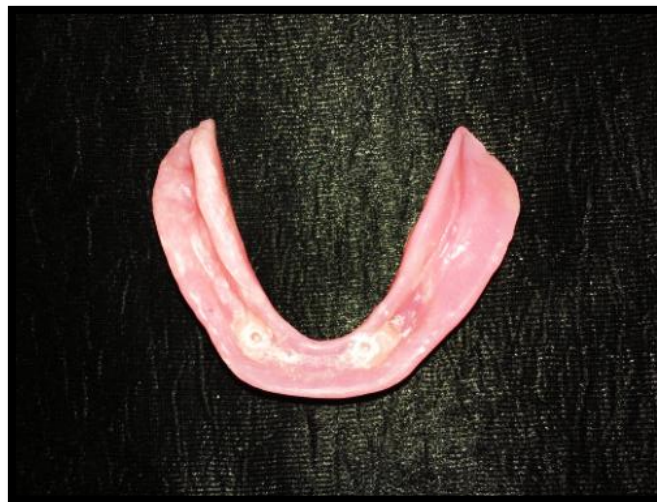PLACEMENT OF GINGIVAL
FORMER AFTER SECOND
STAGE



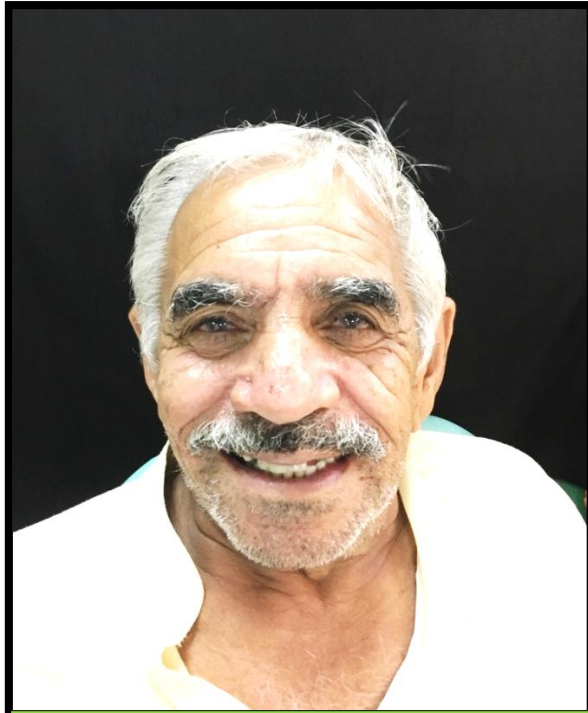
ATTACHMENT OF BALL
ATTACHMENT OVER THE
IMPLANT



FACE BOW RECORD



PICK UP AND RELINING OF NYLON HOUSING



POST TREATMENT PATIENT
FRONTAL PROFILE