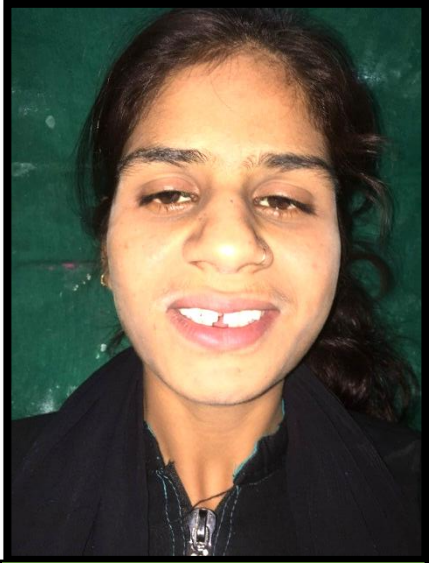

## RESTORATION OF MAXILLARY ANTERIOR MISSING TOOTH USING MARYLAND BRIDGE

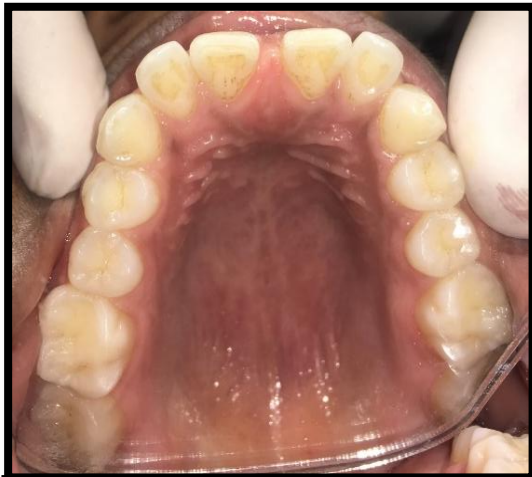<b>NAME</b>	Mrs. Sushma
<b>C R NO.</b>	2017085129
<b>AGE/SEX</b>	22/Female
<b>CHIEF COMPLAINTS</b>	Missing tooth in lower front tooth region from last 2 months and wants the replacement for the same
<b>INTRA- ORAL FINDINGS</b>	<ul style="list-style-type: none"><li>❖ Missing 31 41</li><li>❖ Spacing in upper and lower anteriors</li><li>❖ Adequate inter-arch space</li><li>❖ Calculus and stains present</li></ul>
<b>RADIO GRAPHIC FINDINGS</b>	No relevant radiological findings
<b>DIAGNOSIS</b>	Missing 31 41
<b>TREATMENT EXECUTED</b>	Fabrication of fixed dental prosthesis of missing tooth with loop connector due to wide edentulous area



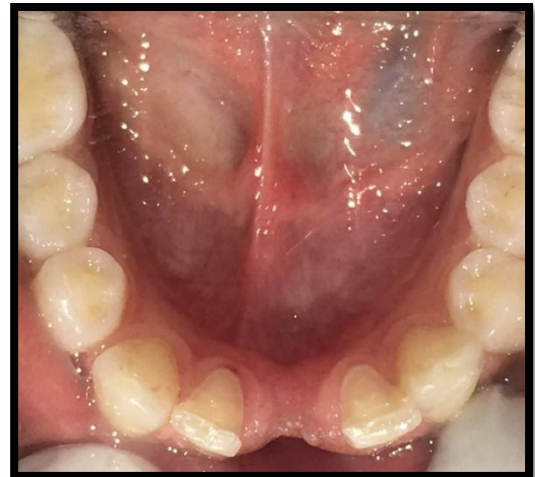Pre treatment patient profile(frontal view)



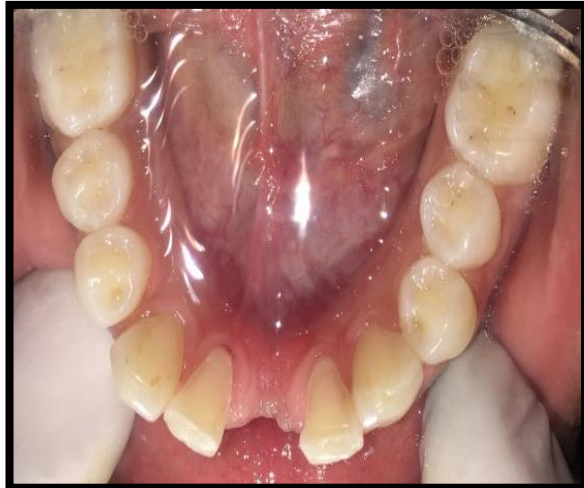Pre treatment patient profile(lateral view)



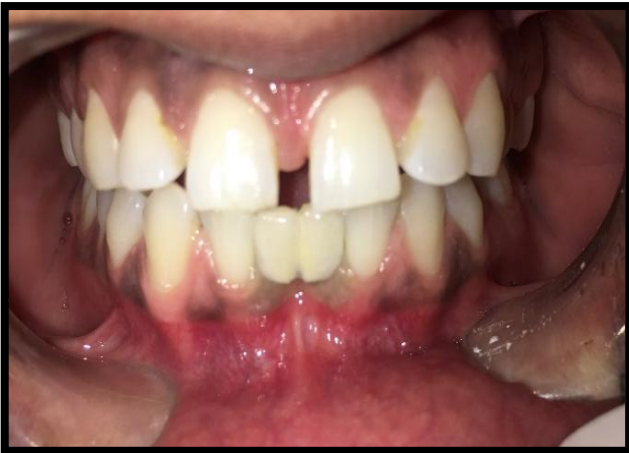MAXILLARY OCCLUSAL VIEW (PRE-OP)



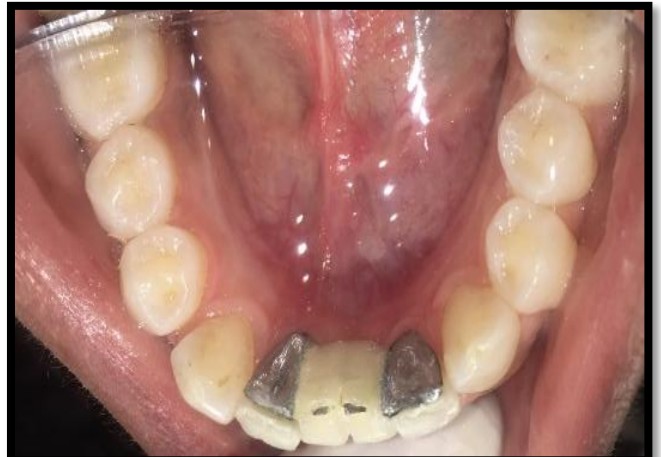MANDIBULAR OCCLUSAL VIEW (PRE-OP)




Tooth preparation



FINAL RESTORATION (LABIAL VIEW)



FINAL RESTORATION (OCCLUSAL VIEW)



Post treatment patient frontal  
profile