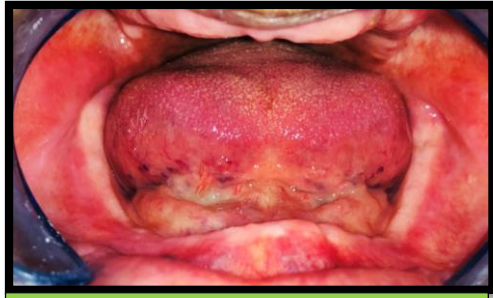
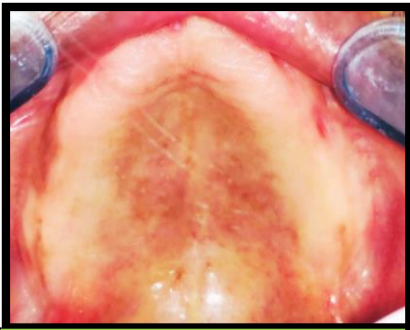
FABRICATION OF COMPLETE DENTURE WITH LINGUALISED OCCLUSION

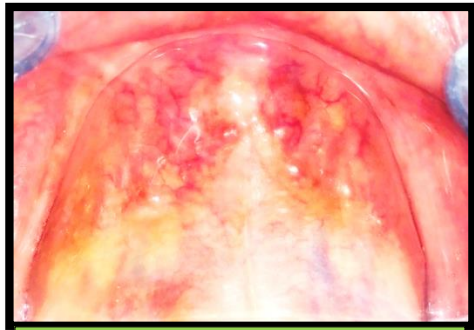
NAME	vasith
C R NO.	20170519162
AGE/SEX	54/male
CHIEF COMPLAINTS	Complain of difficulty in chewing last 3 year
INTRA- ORAL FINDINGS	<ul style="list-style-type: none">❖ Edentulous maxillary and mandibular ridge❖ Adequate inter-arch space
RADIO GRAPHIC FINDINGS	No relevant radiological findings
DIAGNOSIS	Edentulous maxillary and mandibular ridge
TREATMENT EXECUTED	fabrication of complete denture with lingualised occlusion



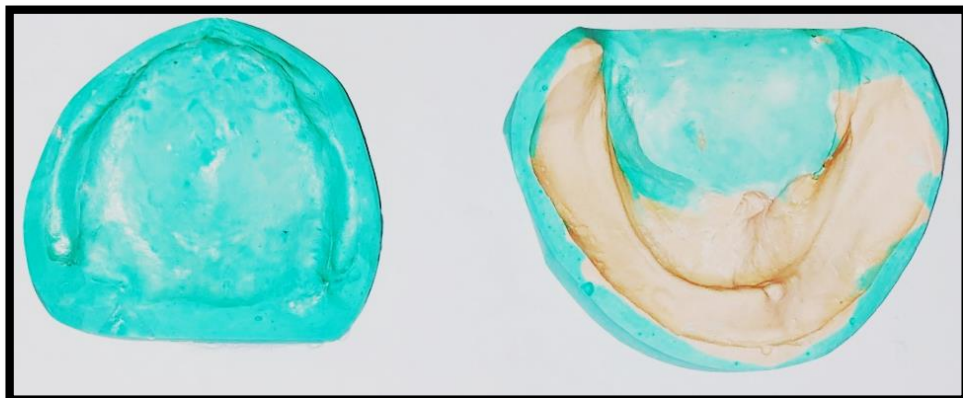
Frontal view of edentulous ridge



Maxillary ridge



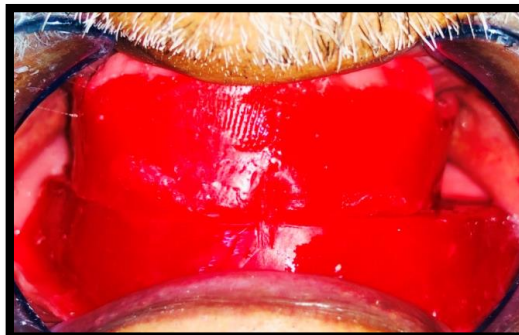Mandibular ridge



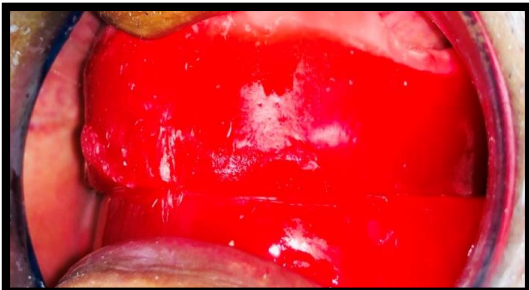
Permanent cast



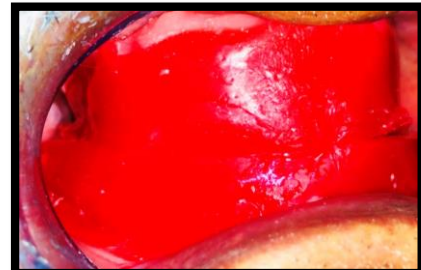Face bow record transfer on semi adjustable articulator



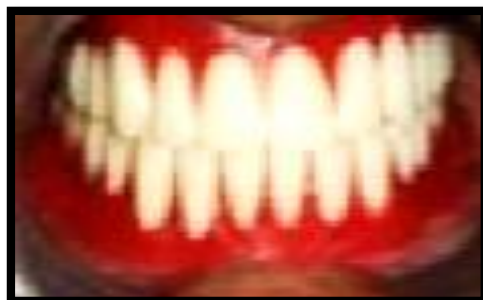Jaw relation



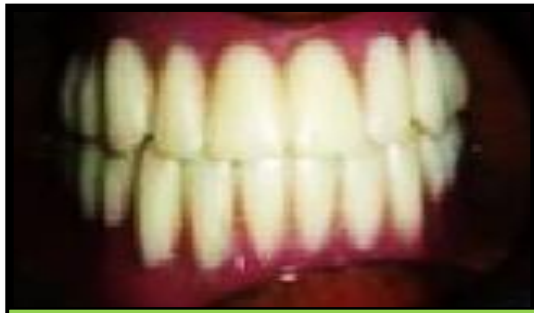Jaw relation



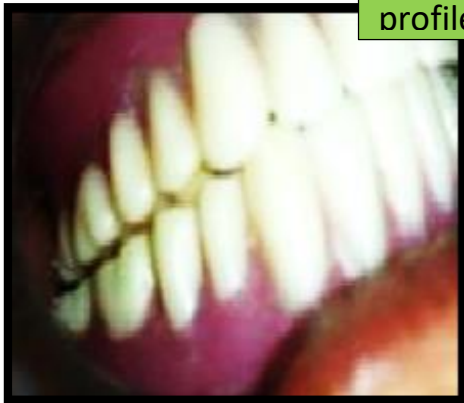
Jaw relation



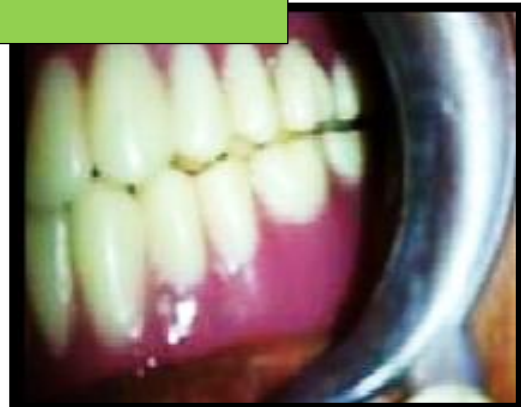Try-in




Prosthesis insertion in frontal profile




Prosthesis insertion in right lateral profile



Prosthesis insertion in left lateral profile



pre treatment frontal profile



Post treatment frontal profile