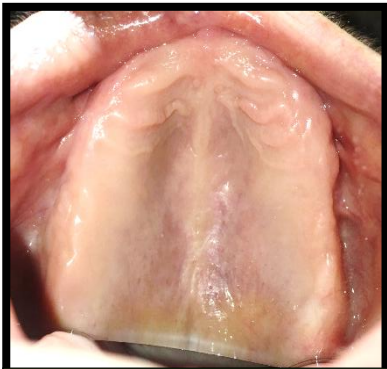


FABRICATION OF COMPLETE DENTURE INCLUDING RUGAE DUPLICATION

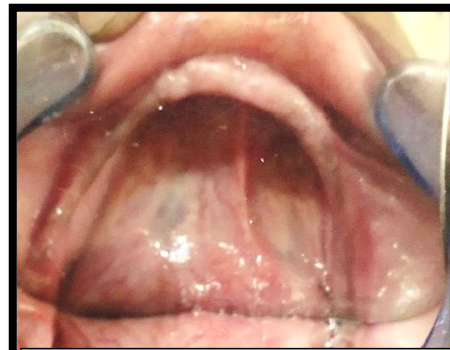NAME	SUDHA
C R NO.	2017022774
AGE/SEX	32/Female
CHIEF COMPLAINTS	Unable to chew last one year
INTRA- ORAL FINDINGS	<ul style="list-style-type: none">❖ Edentulous maxillary and mandibular❖ Adequate inter-arch space
RADIO GRAPHIC FINDINGS	No relevant radiological findings
DIAGNOSIS	<ul style="list-style-type: none">❖ Edentulous maxillary and mandibular ridge
TREATMENT EXECUTED	fabrication of complete denture including rugae duplication



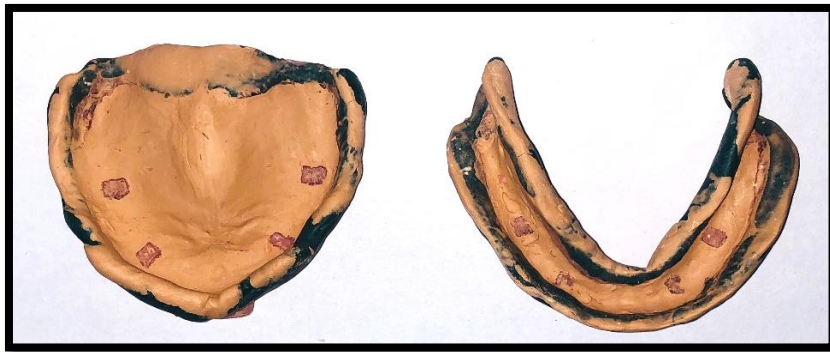Pre-operative profile
photograph



Maxillary ridge



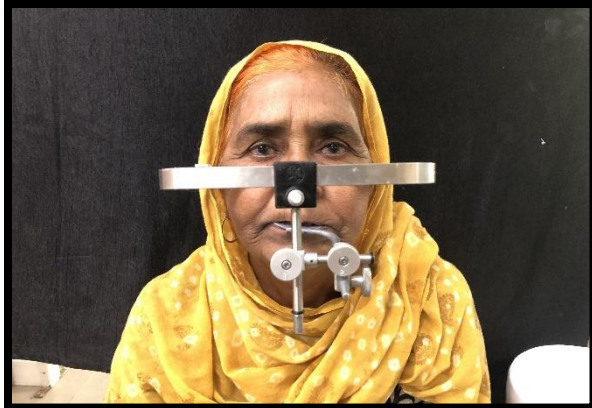Mandibular ridge




Final impression



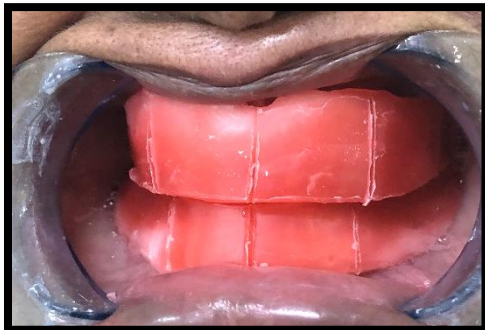
Master cast



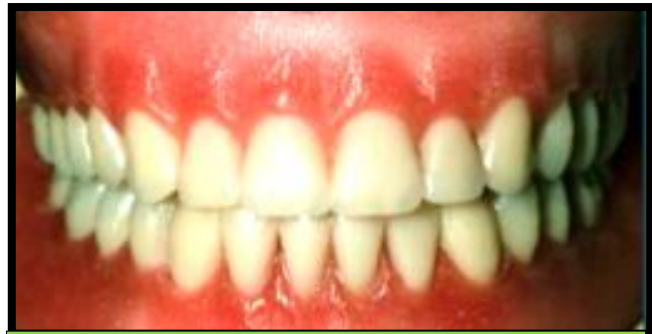Face-bow record



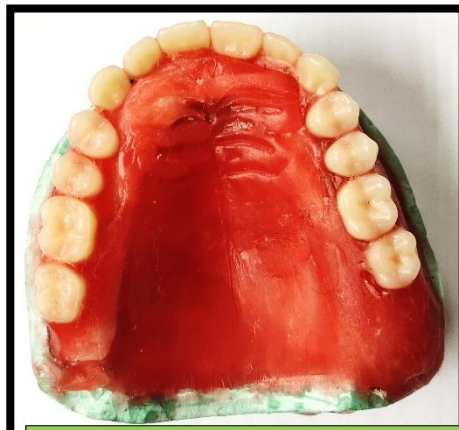
Face bow record transfer on semi adjustable articulator



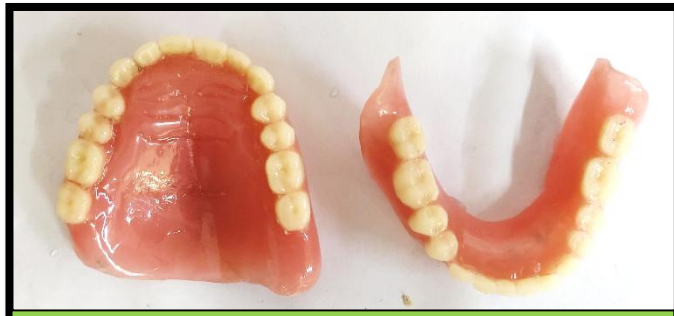Jaw relation



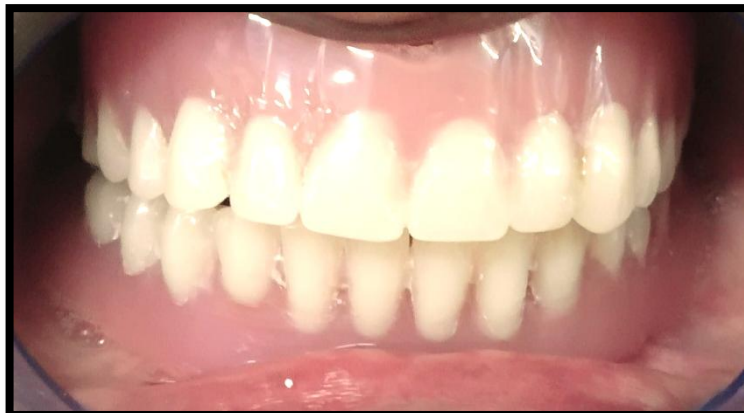Try-in intra-orally



Wax up for rugae duplication



Final prosthesis with rugae duplication



Final insertion of denture



Profile picture after denture insertion