
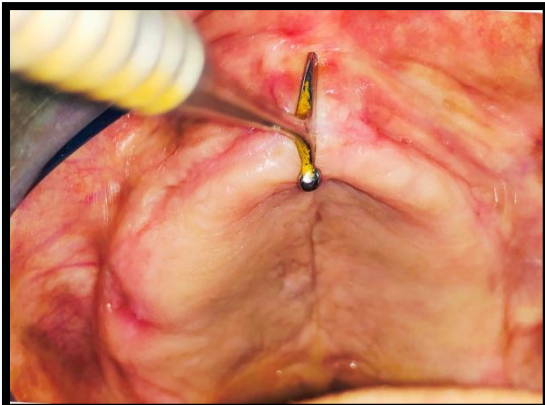


# FABRICATION OF COMPLETE DENTURE USING ZAFARULLAH KHAN TECHNIQUE (FLABBY RIDGE)

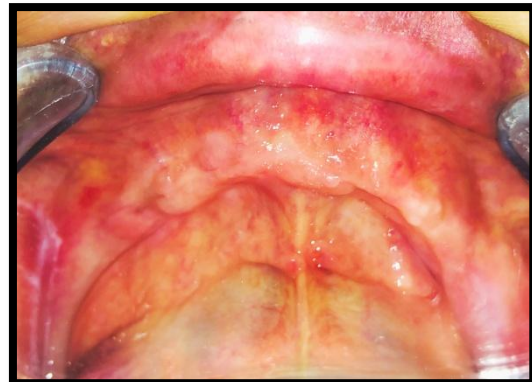<b>NAME</b>	SIYARAM
<b>CR No.</b>	20170216722
<b>AGE/SEX</b>	58/male
<b>CHIEF COMPLAINTS</b>	Complain of difficulty in chewing last 6 year
<b>INTRA- ORAL FINDINGS</b>	<ul style="list-style-type: none"><li>❖ Edentulous maxillary and mandibular ridge</li><li>❖ Adequate inter-arch space</li><li>❖ Flabby tissue in anterior maxillary and mandibular ridge</li></ul>
<b>RADIO GRAPHIC FINDINGS</b>	No relevant radiological findings
<b>DIAGNOSIS</b>	Anterior maxillary and mandibular flabby ridge
<b>TREATMENT EXECUTED</b>	Fabrication of conventional complete denture by using zaffarullah technique



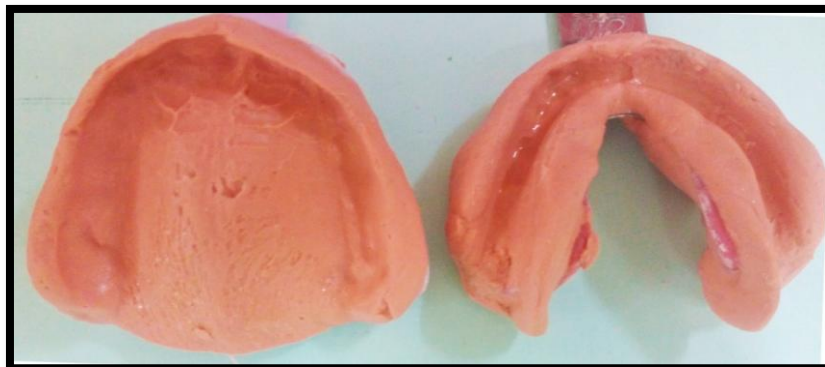Pre treatment patient frontal profile



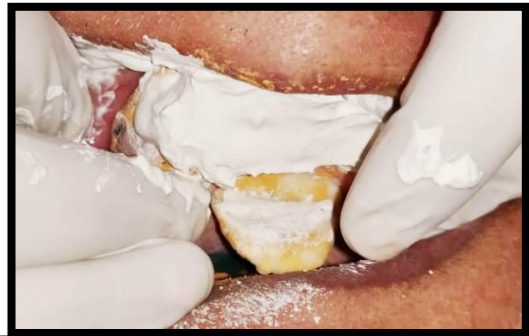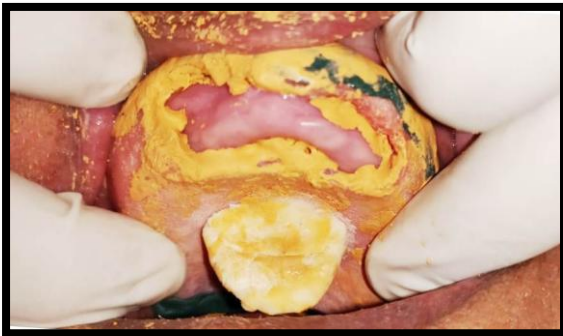Maxillary ridge



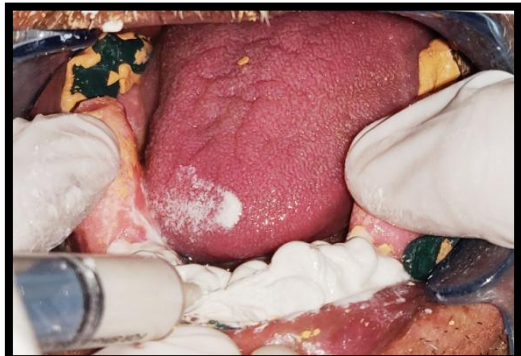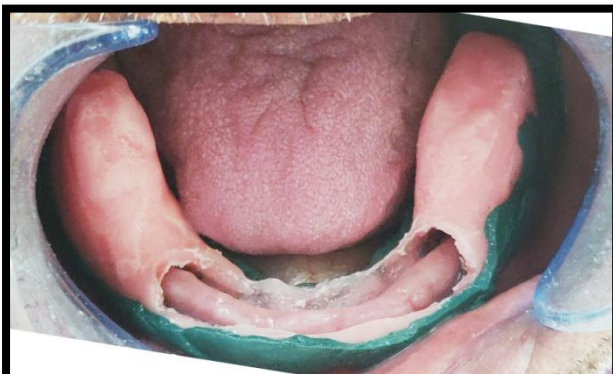Mandibular ridge



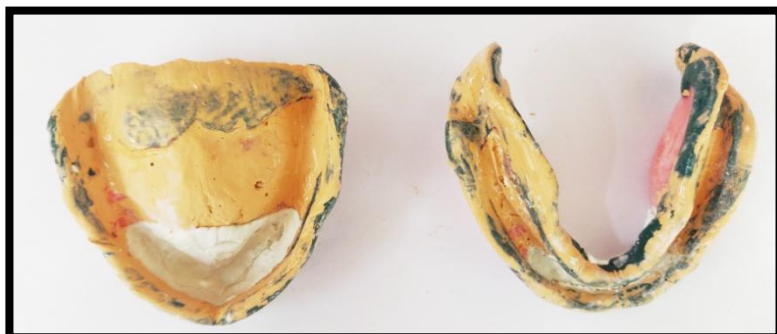Primary impression



Final limpression of maxillary flabby ridge by using zafarulla technique



Final limpression of mandibular flabby ridge by using zafarulla technique



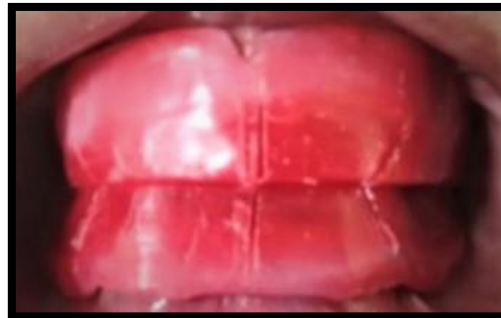Final impression



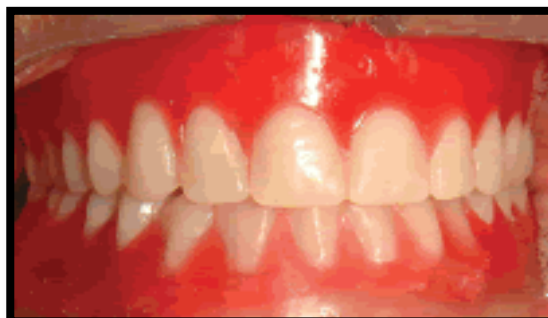Maxillary final cast



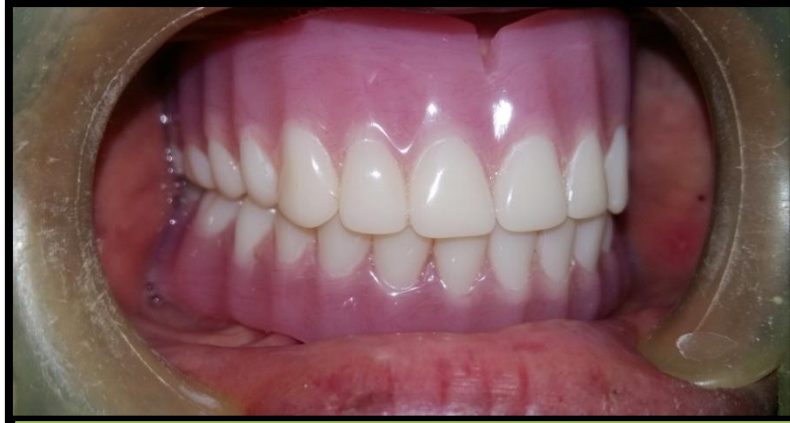Mandibular final cast




Jaw relation



Try In



Insertion of final prosthesis



Post treatment profile photograph