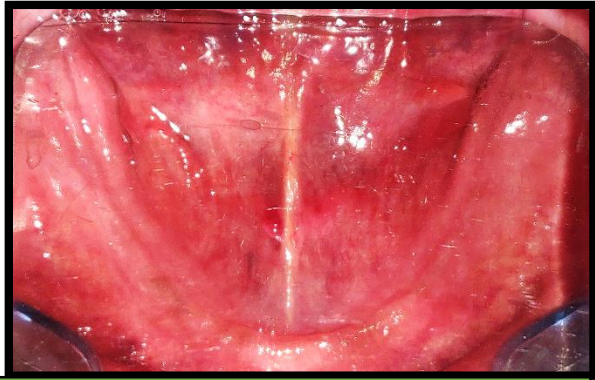
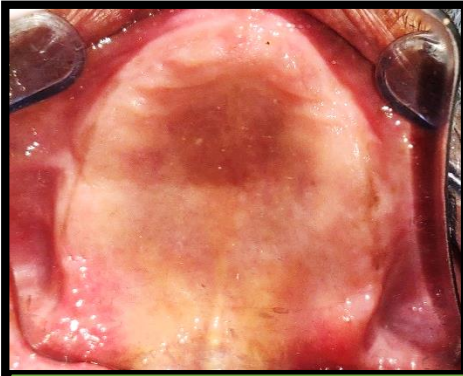
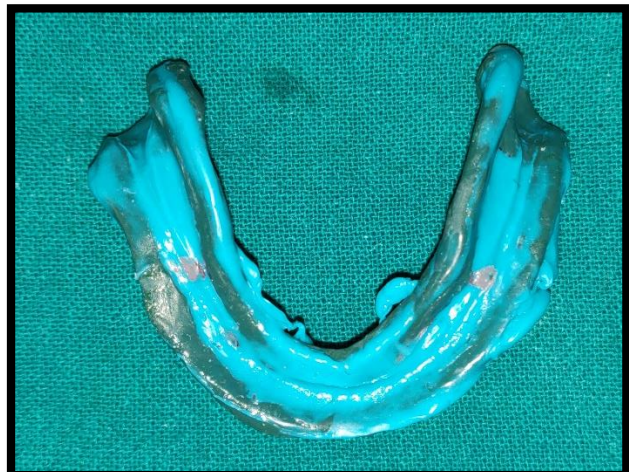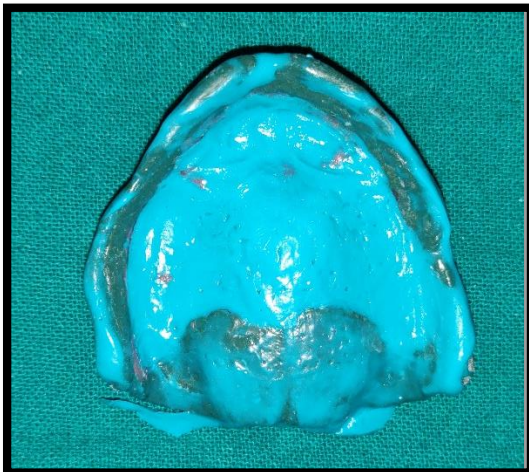


FABRICATION OF COMPLETE DENTURE WITH DETACHABLE CHEEK PLUMPER USING MAGNET

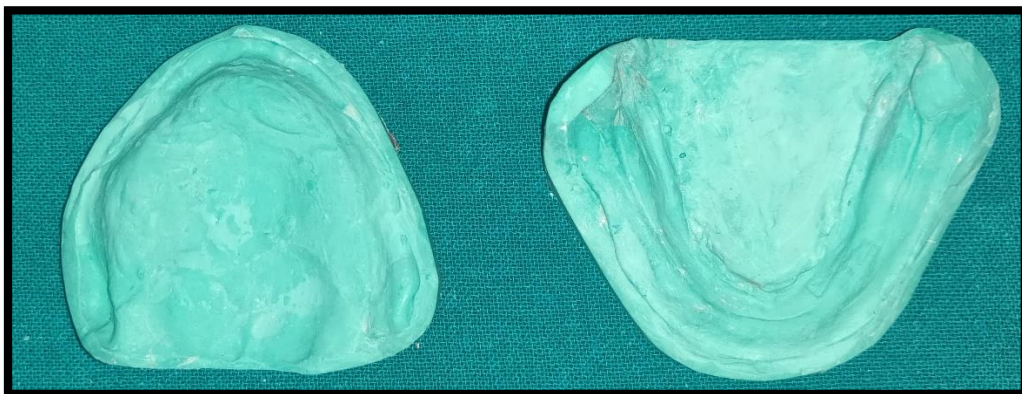
| | |
|-------------------------------|---------------------------------------------------------------------------------------------------------------------------------|
| NAME | Mr. SUNDERLAL |
| C R No. | 20170611142 |
| AGE/SEX | 62/male |
| CHIEF COMPLAINTS | Unable to chew last 5 year year and poor in appearance |
| INTRA- ORAL FINDINGS | <ul style="list-style-type: none">❖ Edentulous maxillary and mandibular ridge❖ Adequate inter-arch space |
| RADIO GRAPHIC FINDINGS | No relevant radiological findings |
| DIAGNOSIS | Edentulous maxillary and mandibular ridge |
| TREATMENT EXECUTED | fabrication of complete denture with detachable cheek plumper using magnet |



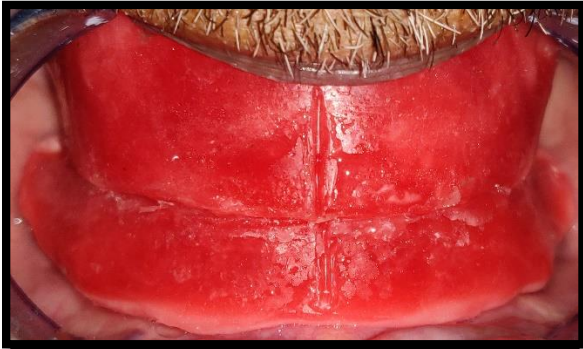
Intra Oral: Maxillary and Mandibular Arches



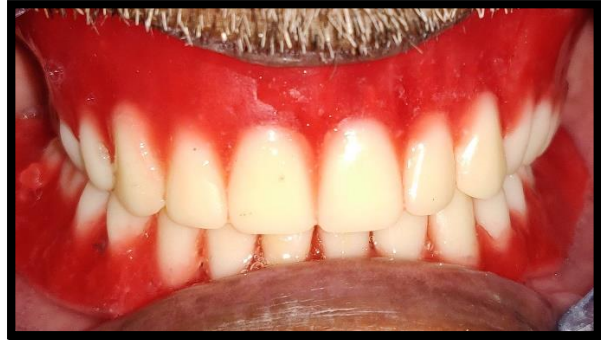Final Impression



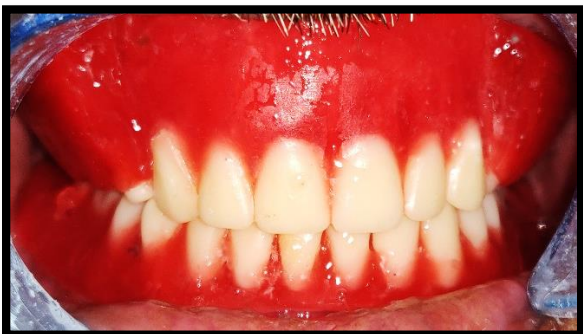Master Casts



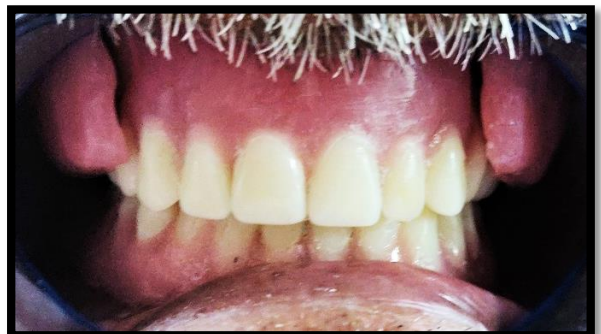Jaw Relation



Try-In



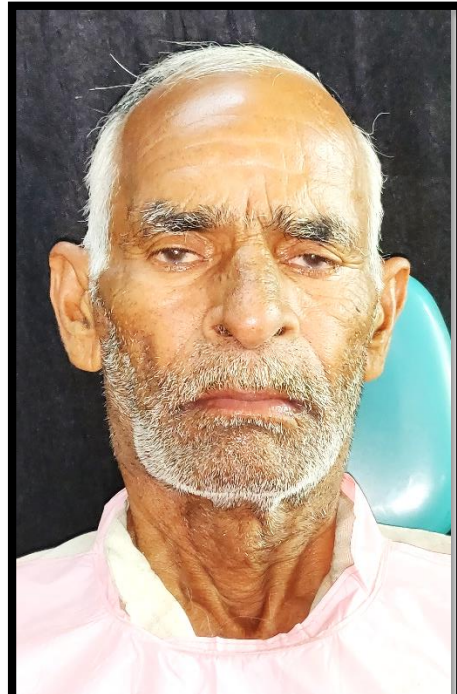
Try-in with Cheek Plumper Wax-up



Insertion



Front Profile: Pre-treatment



Front Profile: Post-treatment